

Postoperative Management of Nasal Vestibular Stenosis

The Custom-made Vestibular Device

Dirk-Jan Menger, MD; Peter J. F. M. Lohuis, MD, PhD;
Steven Kerssemakers, MD; Gilbert J. Nolst Trenité, MD, PhD

Objective: To evaluate the effect of a custom-made postoperative vestibular device on the occurrence and severity of restenosis.

Design: This was a retrospective study conducted at the Department of Otorhinolaryngology/Head and Neck Surgery, Center for Facial Plastic and Reconstructive Surgery of the Academic Medical Center. In this tertiary care center between January 1994 and December 2000, 52 patients treated for nasal vestibular stenosis received a vestibular device directly postoperatively, with the intention to decrease the risk of restenosis. The vestibular device was composed of thermoplastic acrylic material and had a lumen to facilitate breathing. The shape of the device was custom-made within 1 week after surgery and was subsequently worn by the patient for 12 weeks (6 weeks continuously and 6 weeks only during the night). After this period, the occurrence and severity of restenosis of the nasal vestibule were evaluated and the necessity for a potential adjuvant operation was assessed.

Results: Preoperatively, of the 52 patients, 38 (73%) had severe stenosis, 13 (25%) had moderate stenosis, and 1 (2%) had mild stenosis. Postoperatively, 15 (29%) of the patients had mild restenosis, 1 had a case of moderate stenosis, and 1 had a case of severe stenosis. Only the latter patient required a subsequent revision. Functional improvement was noticed in 51 (98%) of the patients, whereas 49 (94%) of the patients showed aesthetic improvement after the initial procedure.

Conclusions: In case of surgical treatment of vestibular stenosis, the use of a custom-made vestibular device may help prevent restenosis. In addition to functional improvement, the device may also improve the aesthetic result. The device does not seem to have any negative adverse effects, was easy to make, and was comfortable for the patient to wear.

Arch Facial Plast Surg. 2005;7:381-386

IN OUR CLINIC, WE FREQUENTLY ENCOUNTER patients with impaired nasal breathing and aesthetic discomfort due to stenosis of the nasal vestibule. Most often, the stenosis is related to a congenital deformation, such as in patients with a cleft lip, or is acquired, as in the case of circumferential scar retraction of the vestibular lining after trauma, infection, or previous surgical procedures.

The treatment of vestibular stenosis is difficult and challenging. In managing this problem, thorough preoperative analysis and meticulous surgical planning are essential for making the procedure successful. When analyzing congenital or acquired vestibular stenosis, it is important to determine the anatomical pathological features. The pathological features can be caused by an aberrant anatomical structure; if not a malformation or a shortage of tissue (soft tissue and/or cartilage).¹ In case of an aberrant anatomical structure, the stenosis can be caused by a deviated caudal septum, a protruding lateral crus,

or a too broad columella. In such cases, reallocation and resection of redundant tissue are sufficient to correct the stenosis, and the chance of developing restenosis is small. For that reason, stenoses caused by aberrant anatomical structures were outside the scope of this study. More complicated surgical techniques are required in case of malformations or shortage of cartilaginous structures and/or the soft tissue envelope. In particular, scar tissue in the soft tissue envelope generally requires resection and replacement by free transplants of skin or auricular composite grafts.² In these cases, the operative techniques are more challenging and postoperative care should be more intensive to reduce the chance of restenosis.

Several studies¹⁻⁵ have shown that adequate postoperative care greatly influences final results. Recurrence of narrowing of the vestibule is a well-known problem after rhinoplastic surgery and is predominantly caused by scar tissue retraction. This is the problem, in particu-

Author Affiliations:
Department of
Otorhinolaryngology/Head and
Neck Surgery, Center for Facial
Plastic and Reconstructive
Surgery, Academic Medical
Center, Amsterdam,
the Netherlands.

lar, in patients in whom the internal nasal valve was involved in the pathology because this specific district requires a laminar flow pattern for sufficient flow and in case of stenosis this region is susceptible to impaired nasal breathing.⁶ The cause of wound contraction is the inward movement of the intact edges of the injured tissue, which occurs during wound healing. The effect of this physiological phenomenon is to decrease the dimension of the area of trauma to its smallest possible extent and is due to the action of fibroblastic differentiation into myofibroblasts.⁷ These myofibroblasts have ultrastructural characteristics of smooth muscle cells and are maximally present in the wound from the 10th until the 21st day. To avoid restenosis, it is necessary to maintain the contour of the nostril during wound contraction.^{1,8} To reach this goal and to prevent restenosis of the vestibule, many researchers⁹⁻¹³ proposed the use of some kind of nasal stenting in the postoperative period. Most of these splints are commercially available and made of elastic silicone or acrylic resin. The vestibular device we used in this study was inspired by the nostril splint,⁹ as described by Nakajima et al.¹⁴ This group used a commercially available nostril splint, on which they placed silicone rubber material on the outside to provide additional support of the vestibule. However, custom-made splints also have been described, such as an expansible splint, used by Costa et al¹³; this splint was only tested on 1 patient. In our view, a vestibulum device should have a perfect fit (ie, a custom-made shape to reach optimal control during the postoperative period), preventing recurrence of stenosis. Therefore, we developed a custom-made vestibular device and tested it on patients with stenosis of the vestibule who underwent rhinoplasty.

METHODS

All patients who received a custom-made vestibular device after surgical treatment for their nasal vestibular stenosis between January 1994 and December 2000 were included in this study. Fifty-two patients (24 males and 28 females) were studied.

PATHOLOGICAL ANATOMICAL FEATURES AND OPERATIVE TECHNIQUES

The indication for surgery in the 52 patients (mean age, 29.1 years; median age, 25.3 years; age range, 3.4-79.1 years) was a unilateral cleft lip in 35 (67%), a bilateral cleft lip in 8 (15%), and narrowing of the vestibule due to previous surgery in 9 (17%) (percentages do not total 100 because of rounding). In all patients, stenosis of the vestibule due to previous surgery was caused by malformations or shortage of cartilaginous structures and/or of the soft tissue envelope. Most often, this was due to overresection of the lateral crus and scar tissue retraction of the vestibule lining. One patient had a shortage of tissue because of surgery of the lateral wall of the vestibule; the surgery was performed because of a melanoma. Surgical correction of vestibular stenosis caused by previous surgery was performed using cartilage and/or composite grafts to reconstruct the nasal skeleton and the soft tissue envelope. An auricular composite graft was especially useful in those patients in whom there was scar tissue in the dome area and overzealous resection of the lateral crus. In 4 patients, irradiated rib cartilage (Tutoplast; Tutogen Medical GmbH, Neunkirchen am Brand, Germany) was used. For the surgical correction of ves-

tibular stenosis in the patients with unilateral and bilateral clefts, an external approach was appropriate, usually with the use of septum (n=22) or ear cartilage (n=16) grafts or an auricular composite graft (n=11). (One patient received both septal cartilage and a composite graft.) Reconstruction of the lower nasal third was performed by reshaping malformed lateral crura with suture techniques and cartilage grafts and medialization of the caudal septum. The alar base was reallocated to a more medial position using a modified Z-plasty. An external approach was performed in 50 (96%) of the patients and an endonasal technique was used in 2 (4%) of the patients, both because of acquired stenosis of the vestibule.

MAKING THE CUSTOM-MADE VESTIBULAR DEVICE

One week postoperatively, immediately after removal of the nasal packing and dressing, a cast of the nose and nasal vestibule was made. For this purpose, hydrophilic vinyl polysiloxane impression material, type regular (EXAMIX), was injected into the vestibule and on the external nose after blocking the nasal cavity posterior to the internal valve area with a 2-cm gauze. Underneath a plastic cap, the material had hardened after 5 minutes and could be removed (**Figure 1A-C**). Of this mold, a plaster of Paris cast model of the nose and nasal vestibules was made by the dental laboratory (**Figure 1D**). Based on this cast, a vestibular device was molded, which was made of thermoplastic acrylic. The design had a lumen so that normal nasal breathing was ensured (**Figure 2**). Patients were asked to wear this device the first 6 weeks continuously; after that, they were asked to wear the device for 6 weeks only at night (**Figure 3**).

DEFINITIONS OF THE SEVERITY OF THE VESTIBULAR STENOSIS

The following items were studied retrospectively and collected in a database: age, sex, cause of stenosis, surgical approach, use of grafts, complications, total follow-up time, aesthetic improvement, functional improvement, and the necessity of revision surgery. Our objective was to study the functional improvement by determining the occurrence and severity of restenosis. For this purpose, we defined 3 levels of severity of the vestibular stenosis and a fourth level of no stenosis in case of a successful postoperative result. Each patient was scored on 3 variables preoperatively and postoperatively. The first level, severe stenosis, was defined as severe stenosis on clinical examination and photography, with continuous obstructive complaints, even at rest. The second level, moderate stenosis, was defined as moderate stenosis on clinical examination and photography, with complaints during mild exercise, like normal walking. The third level, mild stenosis, was defined as mild stenosis on clinical examination and photography, with complaints only during exercise, like running. The fourth level, no stenosis, was defined as no obvious stenosis on clinical examination or photography and no complaints during exercise. The patients were classified in a certain level of severity when at least 2 of 3 variables of that level were scored. In case 3 different levels of severity were scored for each variable, the mean of these levels of severity was chosen for that patient. Postoperative scoring was performed 4 weeks after the 12-week period of wearing the vestibular device. Functional improvement, after the surgical treatment and wearing the vestibular device, was established in case a patient could be classified in at least 1 higher level, as previously defined. Aesthetic improvement was achieved only as the surgeon and the patient concluded an aesthetic improvement had occurred compared with the preoperative condition.

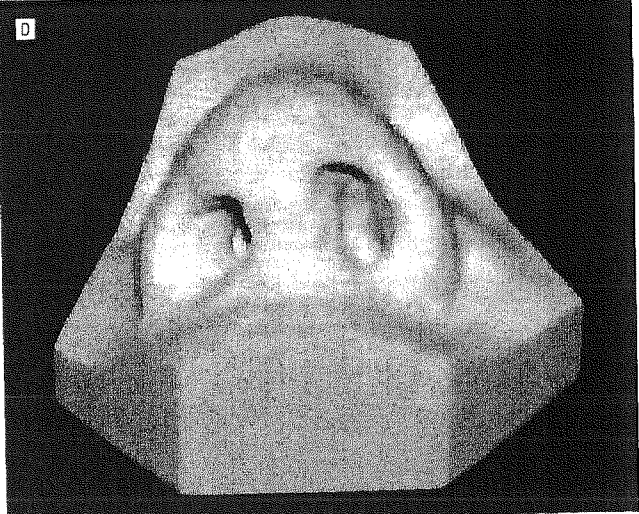
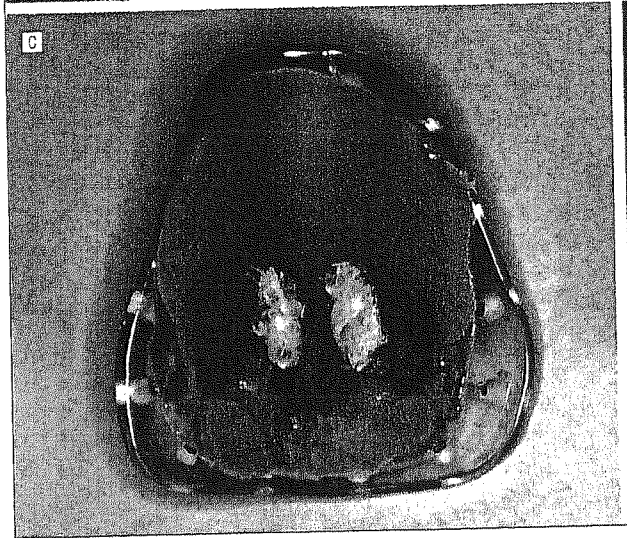
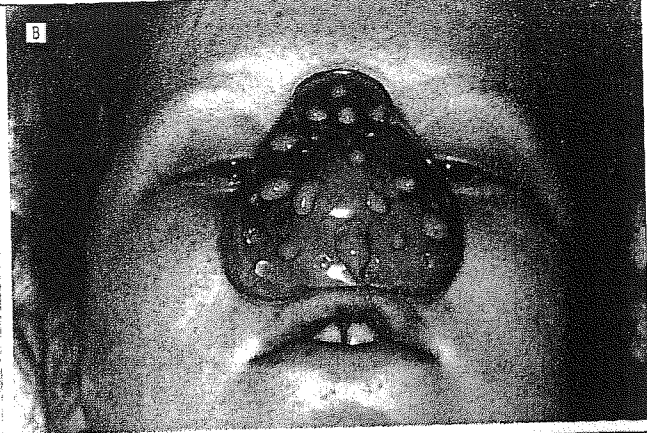
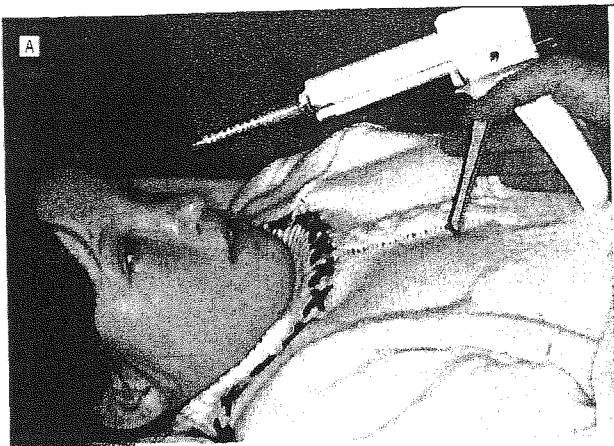


Figure 1. Injection of hydrophilic vinyl polysiloxane impression material (EXAMIX) into the vestibule and on the external nose after blocking the nasal cavity posterior to the internal nasal valve with a 2-cm gauze (A), hardening of the impression material for 5 minutes underneath a plastic cap (B), impression of the nasal vestibules and external nose in the impression material (the 2-cm gauze is visible at the impression of the most posterior part of the vestibule) (C), and plaster of Paris cast of the nose and nasal vestibules (D).

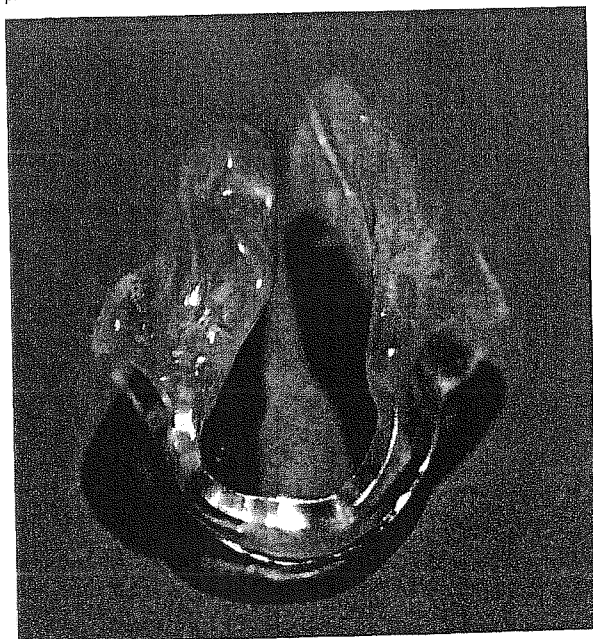

Figure 2. Custom-made vestibular device made of thermoplastic acrylic material with a lumen to facilitate breathing.

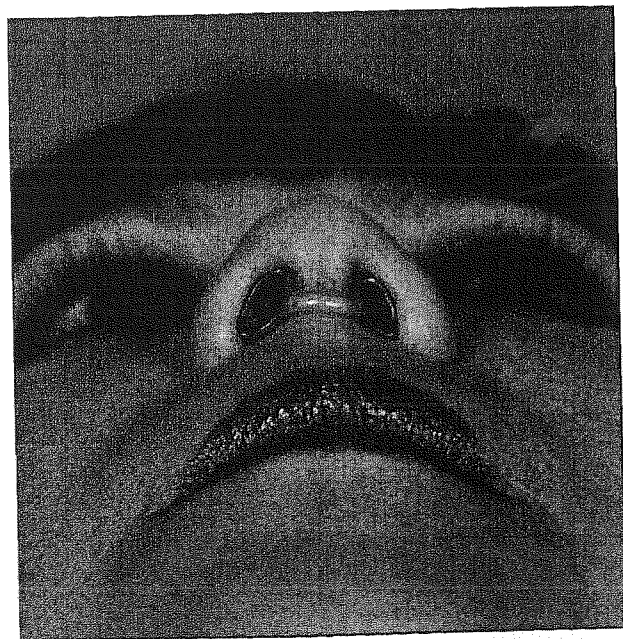


Figure 3. The custom-made vestibular device in situ; a 3-mm-thick transparent band over the columella is visible.

RESULTS

Fifty-two patients (24 males and 28 females) were included in this study. The median time of wearing the device was 12 weeks (range, 6-49 weeks). In one case, in a patient with a unilateral cleft lip, the device was not worn for the full 12 weeks, due to a severe redeviation of the septum. Three patients wore the device for a prolonged period. The reasons for the prolonged application included a severe internal nasal valve insufficiency in 1 patient. Two patients necessitated a prolonged period because of the tendency of restenosis after 12 weeks. The median follow-up was 50.5 weeks, varying from 12 to 310 weeks. Before surgery, 38 (73%) of the 52 patients had severe stenosis; moderate stenosis was seen in 13 (25%) of the patients and only 1 (2%) of the patients had mild stenosis. After surgery, 1 (2%) of the patients had moderate restenosis and 1 (2%) had severe restenosis; 15 (29%) had mild restenosis. Of the 52 patients, 35 (67%) did not have stenosis postoperatively (Figure 4). Of all

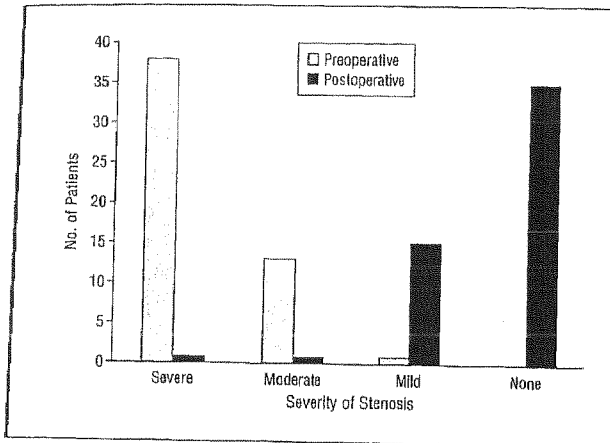


Figure 4. Severity of preoperative and postoperative stenosis. The preoperative bars indicate the number of patients with severe, moderate, and mild stenosis. After surgery, only 1 patient still had severe stenosis; most patients did not have signs or symptoms of vestibular stenosis after wearing the vestibular device.

the patients, 51 (98%) showed functional improvement and 49 (94%) showed aesthetic improvement after the initial procedure, as defined in the "Definitions of the Severity of the Vestibular Stenosis" subsection of the "Methods" section (Figures 5, 6, and 7). Only 1 patient (2%) required revision surgery. This patient did not have functional improvement. Two patients (4%) improved by 1 level of severity, 28 (54%) improved by 2 levels of severity, and 21 (40%) improved by 3 levels of severity. In 6 patients, the device had to be adjusted; and in 3 patients, a new device was made. Reasons for adjustment were a nonfitting device due to postoperative swelling or narrowing of the vestibule in the week between the making of the cast and the wearing of the device. Reasons for making a new device were either a device that was too large and could not be adjusted or a broken device. There was no noncompliance observed due to irritation of the vestibular skin or other problems. For the most part, patients felt comfortable wearing the device.

COMMENT

The nasal vestibule, or the external nasal valve, is the first component of nasal resistance and is composed of the alar cartilage, the columella, the caudal end of the septum, and the soft tissue of the vestibular floor. Just behind this area, the internal nasal valve is situated; this is the narrowest segment of the airway. The internal valve area includes the caudal end of the upper lateral, the nasal septum, the head of the inferior turbinate, the piriform aperture, and the floor of the nose. Narrowing or stenosis in one of these valves results in impaired nasal breathing. In most of our patients in the present study, the stenosis was situated in external and internal valves. Internal valve problems, due to a caudal septum deviation, inferior turbinate hypertrophy, or a protruding lateral crus, and external valve problems, such as slitlike nostrils with weak alae, were outside the scope of this study. This kind of pathological features were excluded because these patients do not need prolonged postoperative care because restenosis is uncommon.

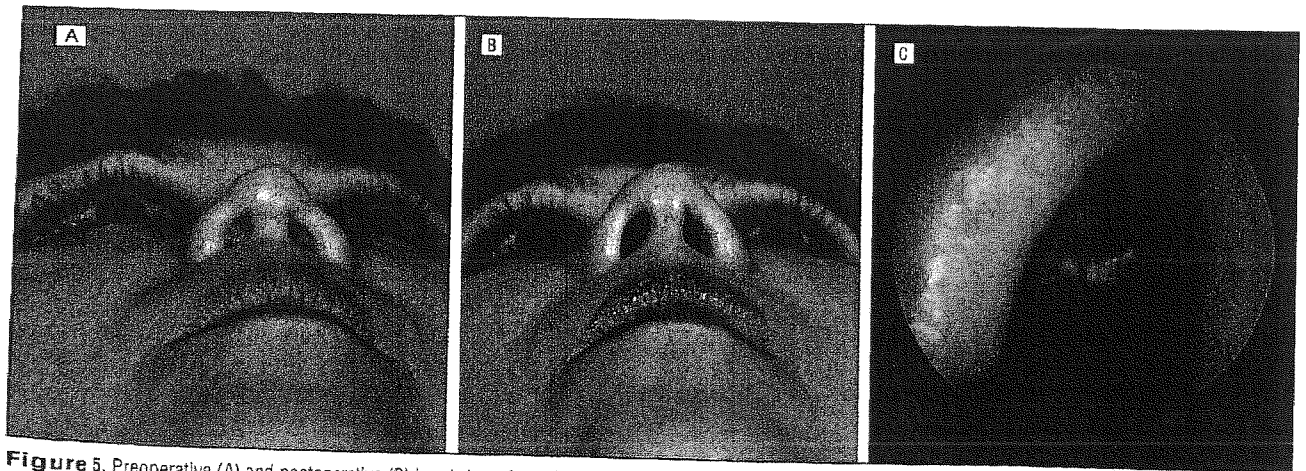


Figure 5. Preoperative (A) and postoperative (B) basal view of a patient with severe vestibular stenosis on both sides due to overresection of the nasal skeleton and soft tissue and preoperative endoscopic view of the vestibule of the same patient (C). The lateral wall of the vestibule is on the left and the nasal septum is on the right side; there were adhesions and synechia due to circular wounds after previous surgery. Reconstruction was performed through an open approach, with the use of auricular composite grafts.

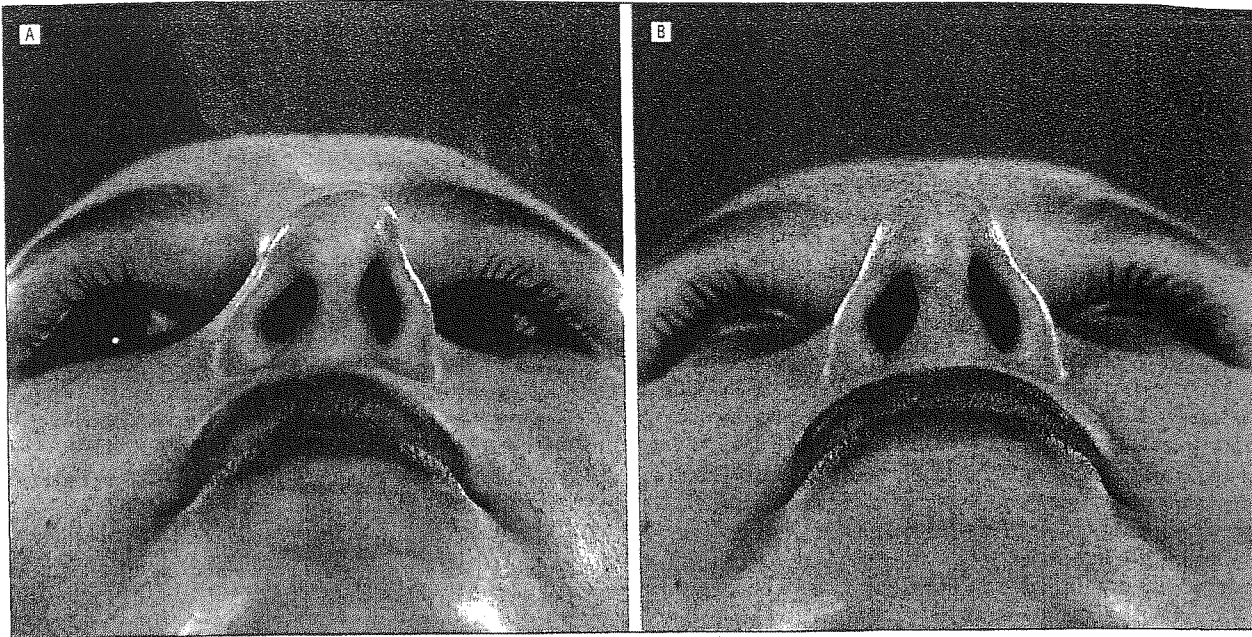


Figure 6. Preoperative (A) and postoperative (B) basal view of a patient with an asymmetric tip and vestibular stenosis due to a unilateral cleft lip on the right side. Surgical correction of the vestibule was performed through an external approach with the use of an autogenous ear cartilage.

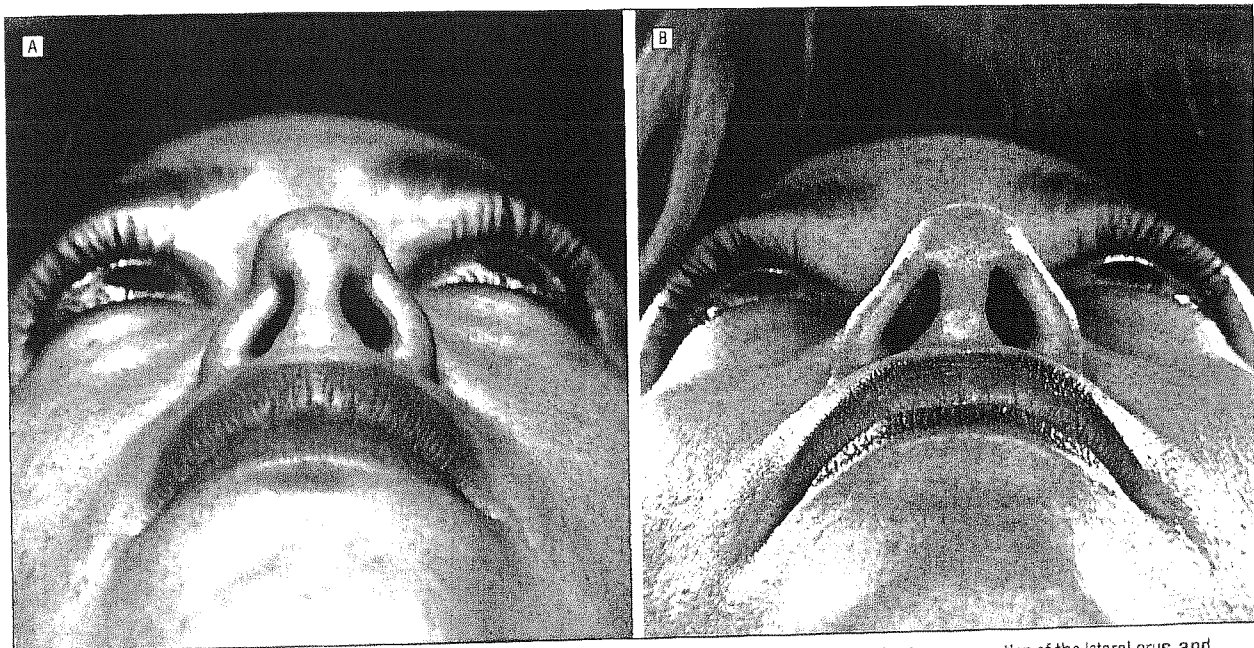

Figure 7. Preoperative (A) and postoperative (B) basal view of a patient with vestibular stenosis on the right side due to overresection of the lateral crus and vestibular skin. By using the external approach and an auricular composite graft, the shape of the vestibule was corrected.

Except for multiple case reports,^{3,12,13} to our knowledge, only one series⁴ about postoperative management of vestibular stenosis has been published in the literature. In this previous series, between January 1988 and January 1994, a group of 52 patients with a cleft lip (5 with bilateral clefts and 47 with completely unilateral clefts) were studied. In this population, there was a postoperative recurrence of 10%, with more narrowing of the vestibule than in the preoperative situation. These patients required revision surgery. In the present study, there was no control group. However, even if a control group

was included, we believe that it would be extremely difficult to randomize for the amount of vestibular pathological features, which by themselves may already influence outcome. Moreover, based on the good results we had with the vestibular device in the previous study, it seemed inappropriate to withhold from patients in a control group this adjuvant treatment possibility postoperatively.

We found that the custom-made vestibular device had a positive effect on maintaining the shape/contours of the nostril postoperatively, and we, thus, believe it has a posi-

tive effect on functional and aesthetic outcome. Other aspects of this device should be considered as well. The device could give local irritation, especially if not fitted adequately. This required an adjustment of the device; in 3 patients, a new and better-fitting device was to be made. In our study, no noncompliance was found because of irritation of the vestibular skin. Another factor was psychological. Although no patient in our group felt uncomfortable wearing the device, patients had to wear the device continuously during the first 6 weeks. Because there was the possibility that patients should feel uncomfortable wearing the device near other people, we designed the custom-made device in such a manner that as little as possible was visible externally. Only a 3-mm transparent band over the columella connected the 2 intranasal parts (Figure 3).

In conclusion, vestibular stenosis has a high risk of restenosis after surgical treatment due to wound contraction during wound healing. The use of a custom-made vestibular device may help reduce the chance of developing restenosis. In addition to functional improvement, the device also seems to improve the aesthetic result. The device does not seem to have any negative adverse effects, was easy to make, and was comfortable for the patient.

Accepted for Publication: June 27, 2005.

Correspondence: Dirk-Jan Menger, MD, Department of Otorhinolaryngology/Head and Neck Surgery, Center for Facial Plastic and Reconstructive Surgery, Meibergdreef 9, 1105 AZ Amsterdam, the Netherlands (d.j.menger@amc.uva.nl).

REFERENCES

1. Nolst Trenite GJ, de Vries X. Nasal vestibular stenosis. *Face*. 1998;5:137-149.
2. Constantian MB. Indications and use of composite grafts in 100 consecutive secondary and tertiary rhinoplasty patients: introduction of the axial orientation. *Plast Reconstr Surg*. 2002;110:1116-1133.
3. al-Qattan MM, Robertson GA. Acquired nostril stenosis. *Ann Plast Surg*. 1991;27:382-386.
4. Kotzur A, Gubisch W, Meyer R. Stenosis of the nasal vestibule and its treatment. *Aesthetic Plast Surg*. 1999;23:86-92.
5. Nolst Trenite GJ. Nasal vestibular stenosis. In: *Rhinoplasty, a Practical Guide to Functional and Aesthetic Surgery of the Nose*. Amsterdam, the Netherlands: Kugler Publishers; 1998:225-236.
6. Mlynski G, Grutzenmacher S, Plontke S, Mlynski B, Lang C. Correlation of nasal morphology and respiratory function. *Rhinology*. 2001;39:197-201.
7. Rungger-Brändle E, Gabbiani G. The role of cytoskeletal and cytocontractile elements in pathologic processes. *Am J Pathol*. 1983;110:361-392.
8. Trenite GJ, Paping RH, Trenning AH. Rhinoplasty in the cleft lip patient. *Cleft Palate Craniofac J*. 1997;34:63-68.
9. Blandini D, Tremolada C, Beretta M, Mascetti M. Iatrogenic nostril stenosis: aesthetic correction using a vestibular labial mucosa flap. *Plast Reconstr Surg*. 1995;95:569-571.
10. Dhanraj P. The use of a suction tube as a nostril retainer. *Plast Reconstr Surg*. 1994;93:643-645.
11. Gregory G, Das Gupta R, Morgan B, Bounds G. Polyvinylsiloxane dental bite registration material used to splint a composite graft of the nasal rim. *Br J Oral Maxillofac Surg*. 1999;37:139-141.
12. Ramstad T, Bretteville G. Nasal stenosis after operations on the nose: expansion and subsequent maintenance of the nasal airway: case report. *Scand J Plast Reconstr Surg Hand Surg*. 1994;28:235-238.
13. Costa P, Orlando A, Di Mascio D. An expansible splint for treatment of nostril stenosis. *Ann Plast Surg*. 1995;34:197-200.
14. Nakajima T, Yoshimura Y, Sakakibara A. Augmentation of the nostril splint for retaining the corrected contour of the cleft lip nose. *Plast Reconstr Surg*. 1990;85:182-186.